


# labline

DENTAVANTGART

VOLUME III, ISSUE #02 SUMMER, 2013.



PIETRO  
VENEZIA MD, DDS  
&  
PASQUALE  
LACASELLA, ODT

**A NEW  
APPROACH**

JOSHUA  
POLANSKY

**DEMYSTIFYING  
THE SINGLE  
CENTRAL  
METHODS**

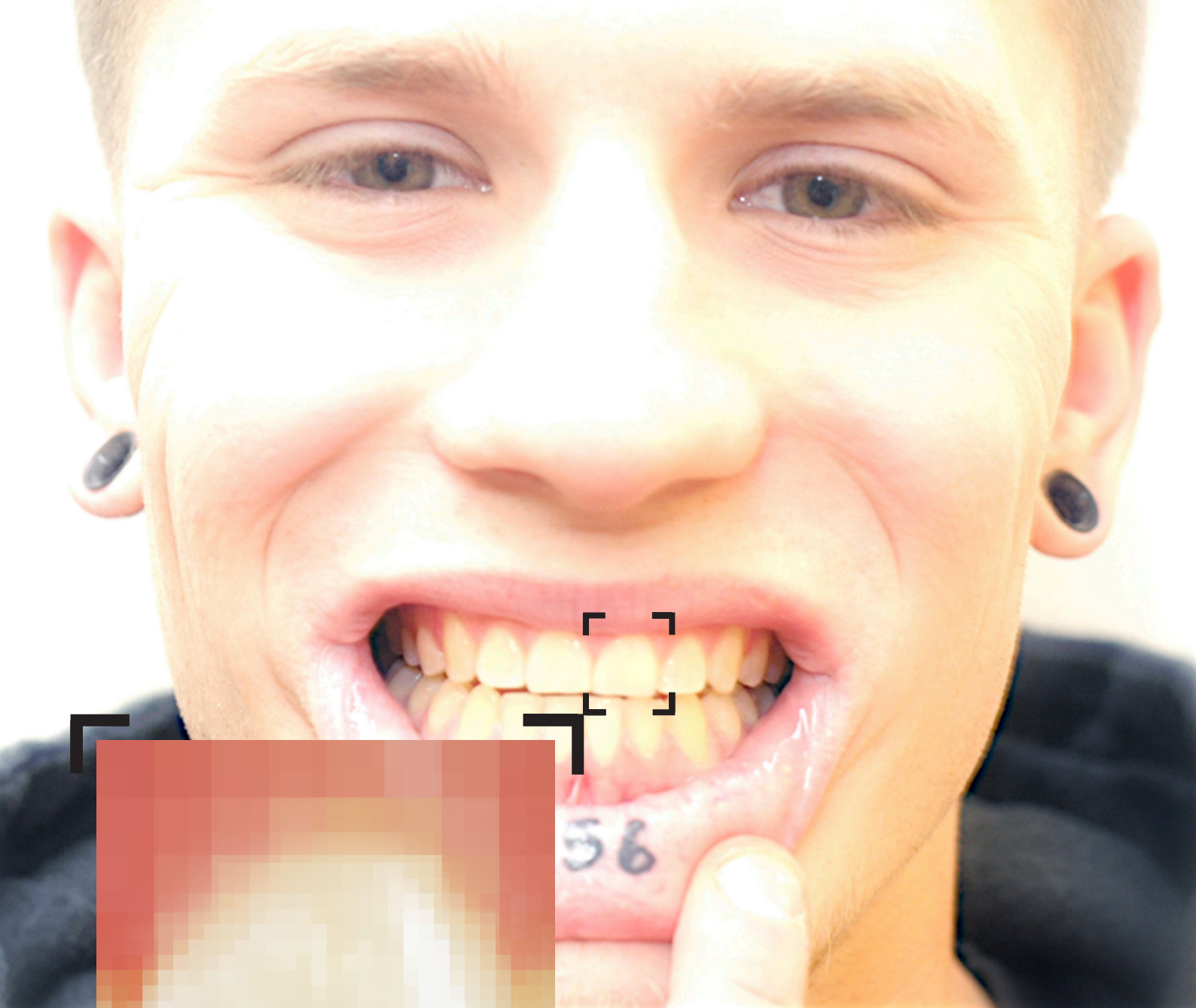DR. JON  
GURREA  
&  
AUGUST  
BRUGUERA

**GONE IN  
48 HOURS**

DR. JORDI  
MANAUTA  
&  
DR. GAETANO  
PAOLONE  
&  
DR. WALTER  
DEVOTO

**IN 'N OUT**






Joshua Polansky

# DEMYSTIFYING THE SINGLE CENTRAL METHODS

...init demistify.proc  
target locked  
MAG.: 6,2X  
demistify in progress  
please wait...  
⌂  
100% completed

## APPLICATIONS AND TECHNIQUES TO CONQUER THE SINGLE CENTRAL

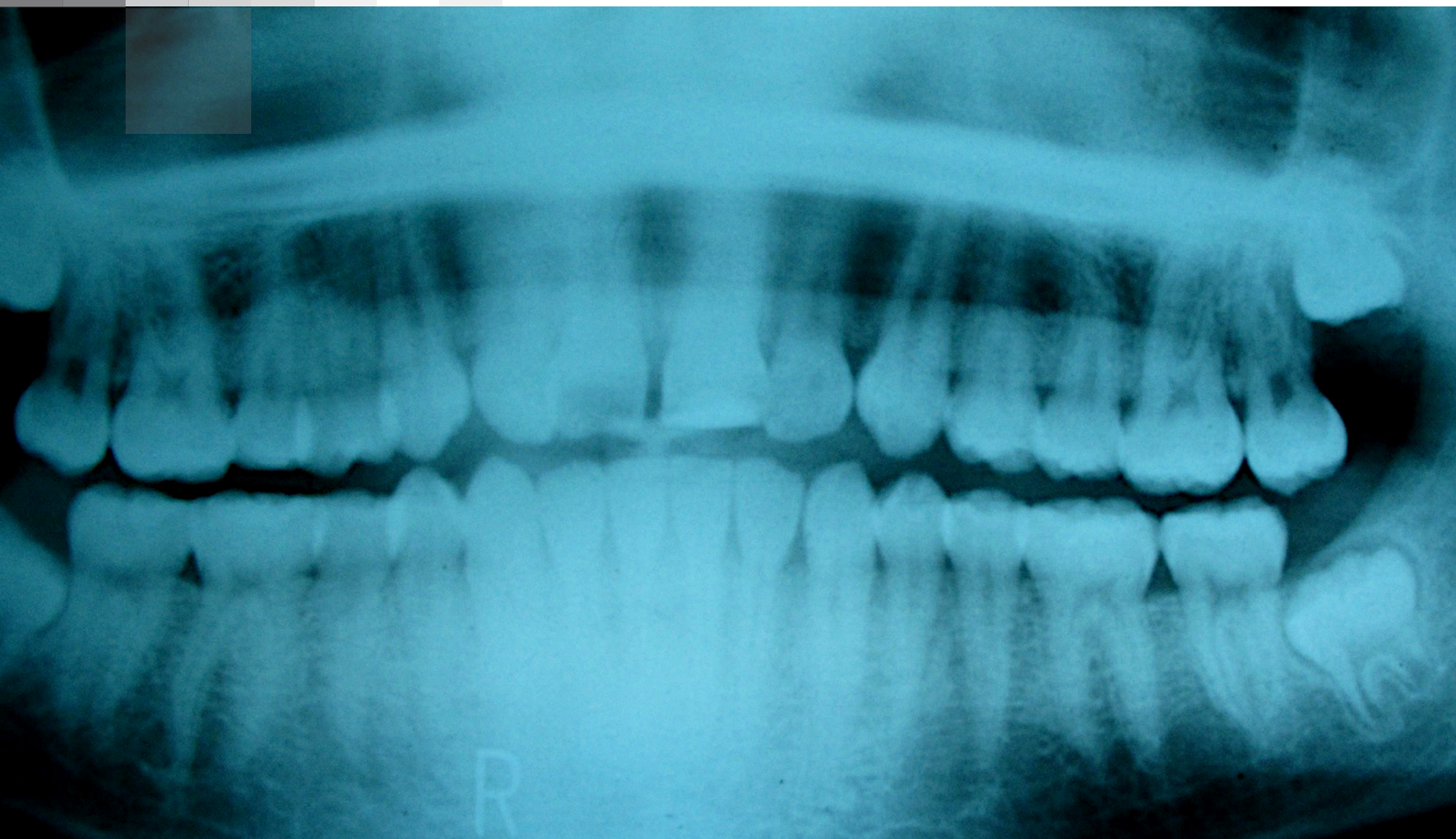


The single central poses problems for technicians around the world. Form, material selection and colour are usually variables that make the task of restoring a single central very difficult. Restoring a single central requires a lot of information, even though only one tooth is to be restored. Open communication between the patient, the technician and the dentist is the first step towards a successful restoration. The following article suggests other variables that will aid in the success of restoring the daunting single central.

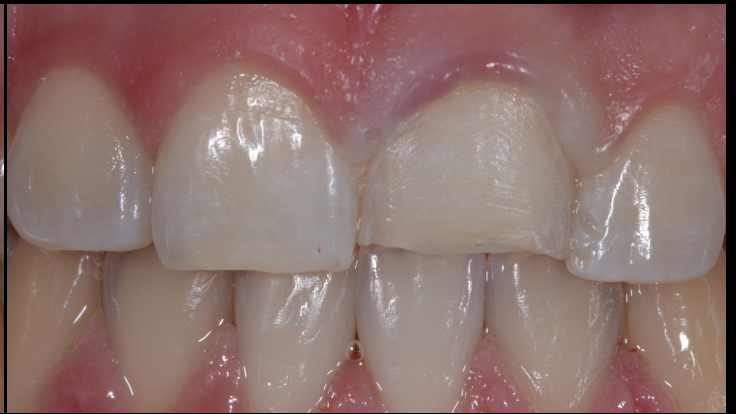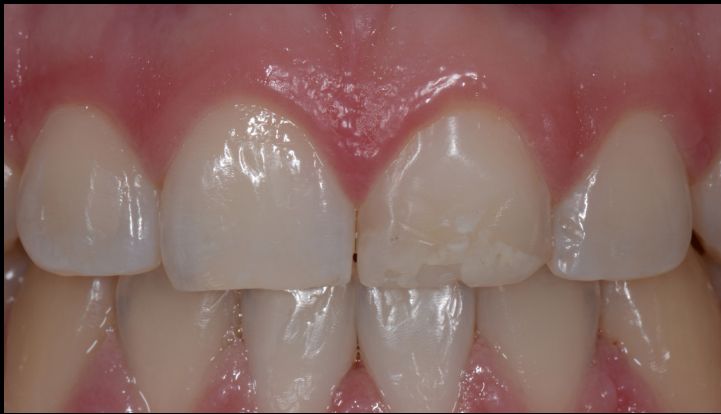### CASE STUDY

#### 01.

Whether it is a matter of a single central or a full mouth, the dental team must first establish a treatment plan for the best possible outcome. In this case, even though only one tooth was to be restored, the restorative team agreed that orthodontics should be the first necessary step in order to achieve an ideal restoration.





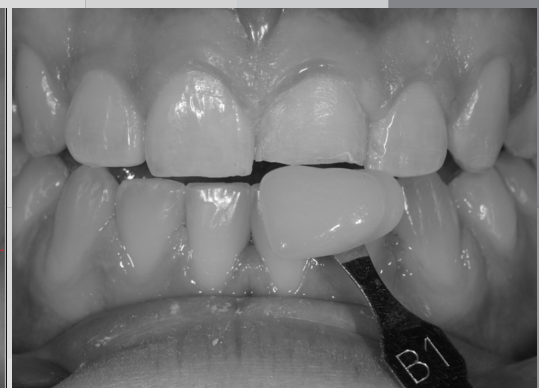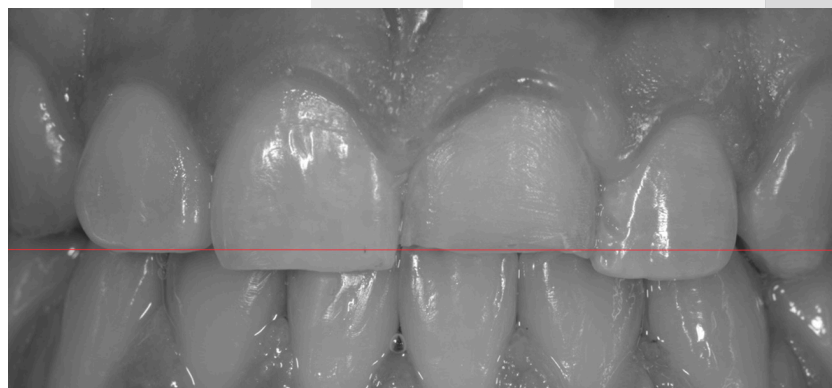


**02.**  
Once the orthodontic treatment was completed the restorative team had a better foundation to build upon.

**03.**  
After the dentition has been aligned for a better restorative outcome it is also crucial to observe the underlying dentition.



**04.**  
This enables the dental technician to obtain an overall view of what's underneath.



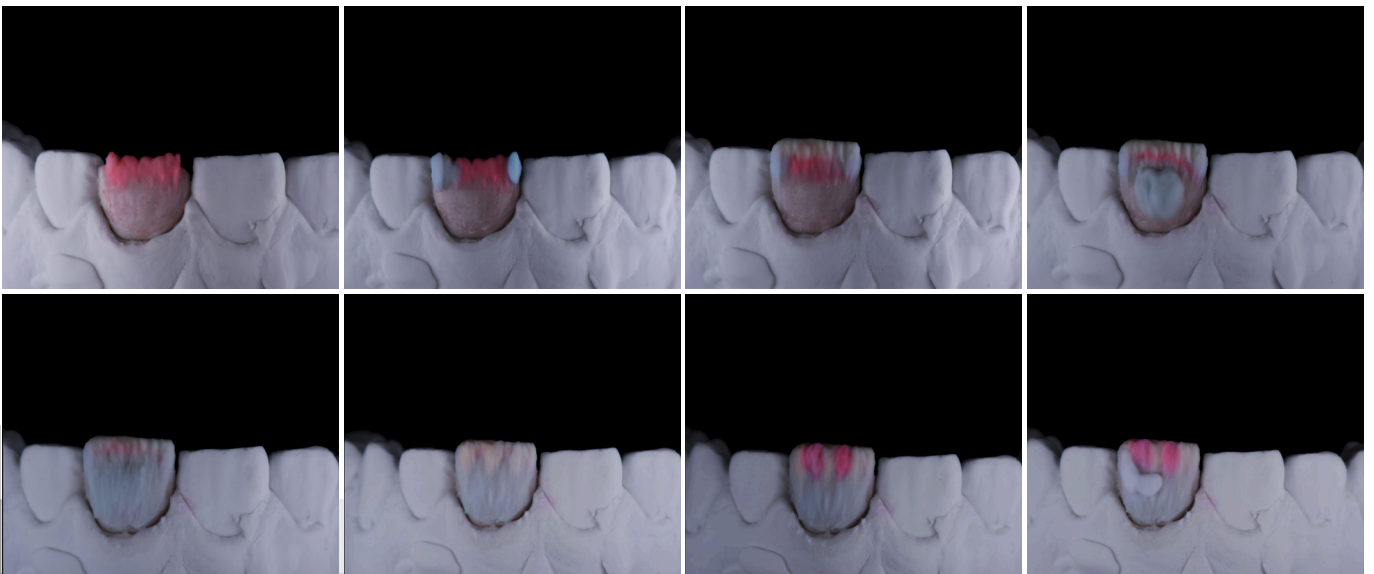
**05.**  
It thus becomes clear what can be used and what must be blocked out when fabricating the restoration. As this case involved minimal facial reduction, it is clear that the goal was to use the abutment colour, and to avoid an incisal demarcation from the shorter preparation.






#### 06.

In this case an alveolar model was fabricated using refractory die technique.



#### 07.

Layering was carried out using GC initial MC ceramic. Care was taken to block out the shorter incisal line using fluorescent dentins to give a smooth transition at the incisal edge of the final restoration.



#### 08.

Extra care must always be taken when layering in a single firing.



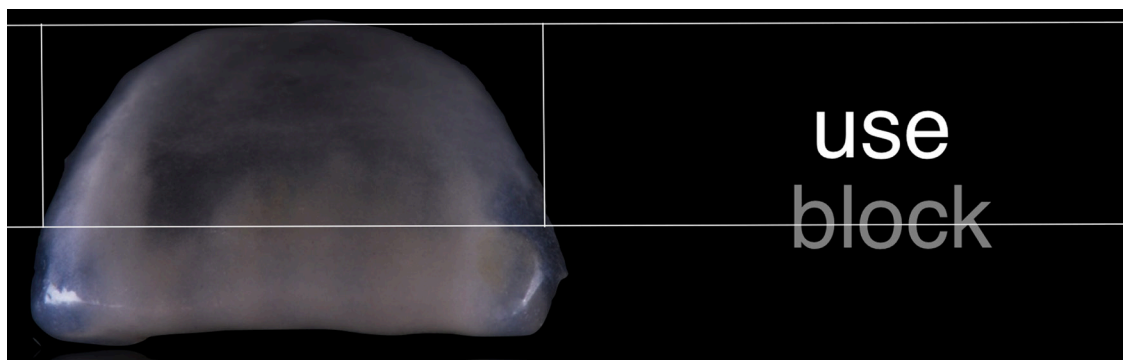
**09.**  
After the first firing  
the final counterling is  
performed out using  
rotary instruments  
in order to achieve  
the final form before  
glazing.

**10.**  
The model should be ob-  
served from every angle using  
different types of lights to  
examine every detail. Once  
the final form is obtained  
the restoration is glazed. A  
step often overlooked in  
fabricating restorations is  
post-glazing treatment. From  
the original images taken the  
technician should also polish  
and finish the veneer to the  
proper lustre.

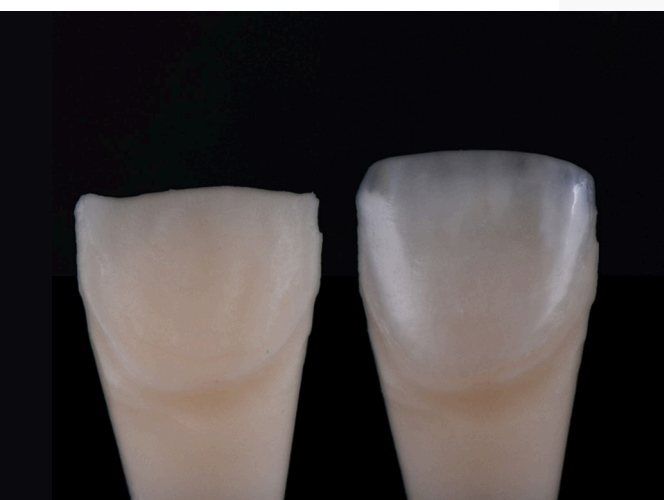
**11.**  
Even if the colour is perfect,  
a different lustre and shine  
will distort the colour opti-  
cally. Once the final polish is  
finished the margin is trimmed  
under a microscope, the root  
section of the die cut off with  
a diamond disc, and the re-  
fractory material sandblasted.

**12.**  
Once the veneer is  
fitted, the precision  
fit can be seen, and  
total overall usage of  
the natural underlying  
abutment colour may  
be observed.

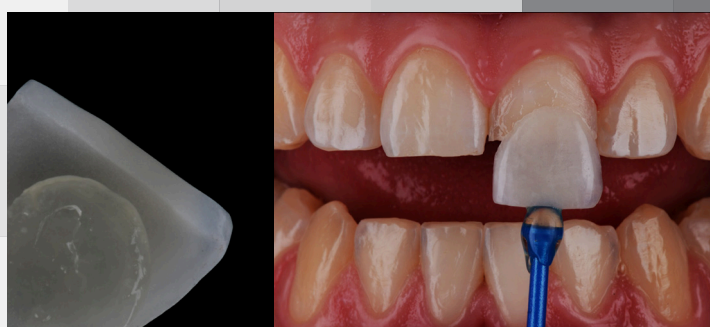




- 13.** Observing the veneer it is clear that care was taken on what to block out and what to use according to the information received from observing the natural abutment colour.



- 14.** An extra check to observe the veneer is to pour a die from the refractory mould in the actual shade of the natural abutment with a New Outline from Anaxdent.

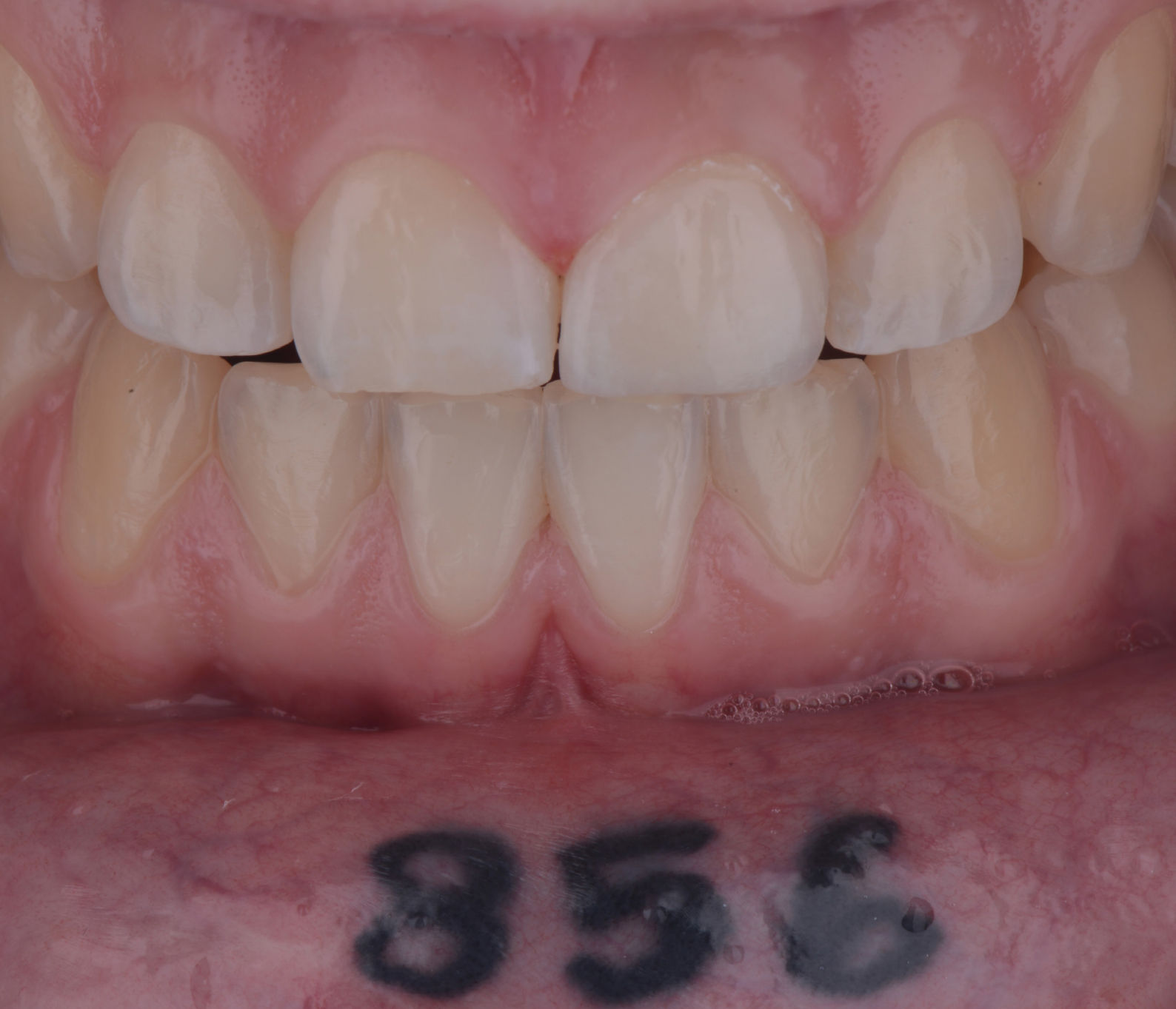

- 15.** This allows the technician to visualise the final colour from the bench. The veneer is then tried intra-orally using Coco butter from GC. In a saturated image it can be seen how the veneer picks up the underlying abutment colour in order to aid in achieving the proper value in the restoration.



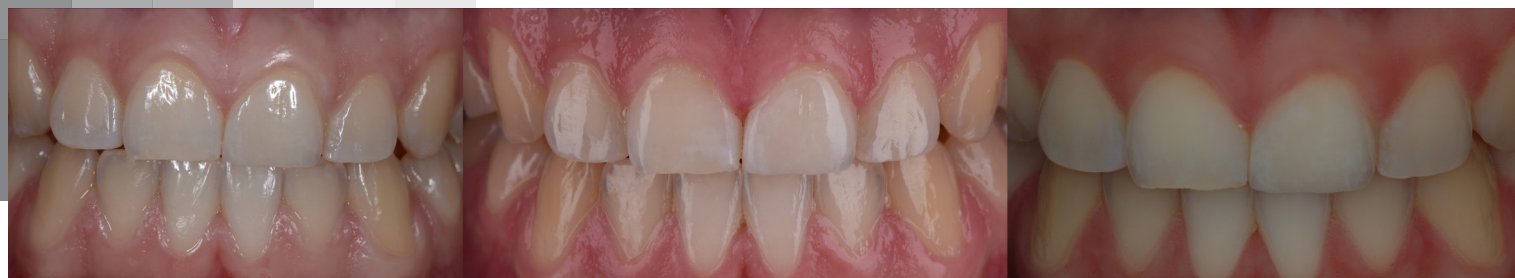- 16.** Once everything has been checked and approved the veneer is fixed.





**17.**

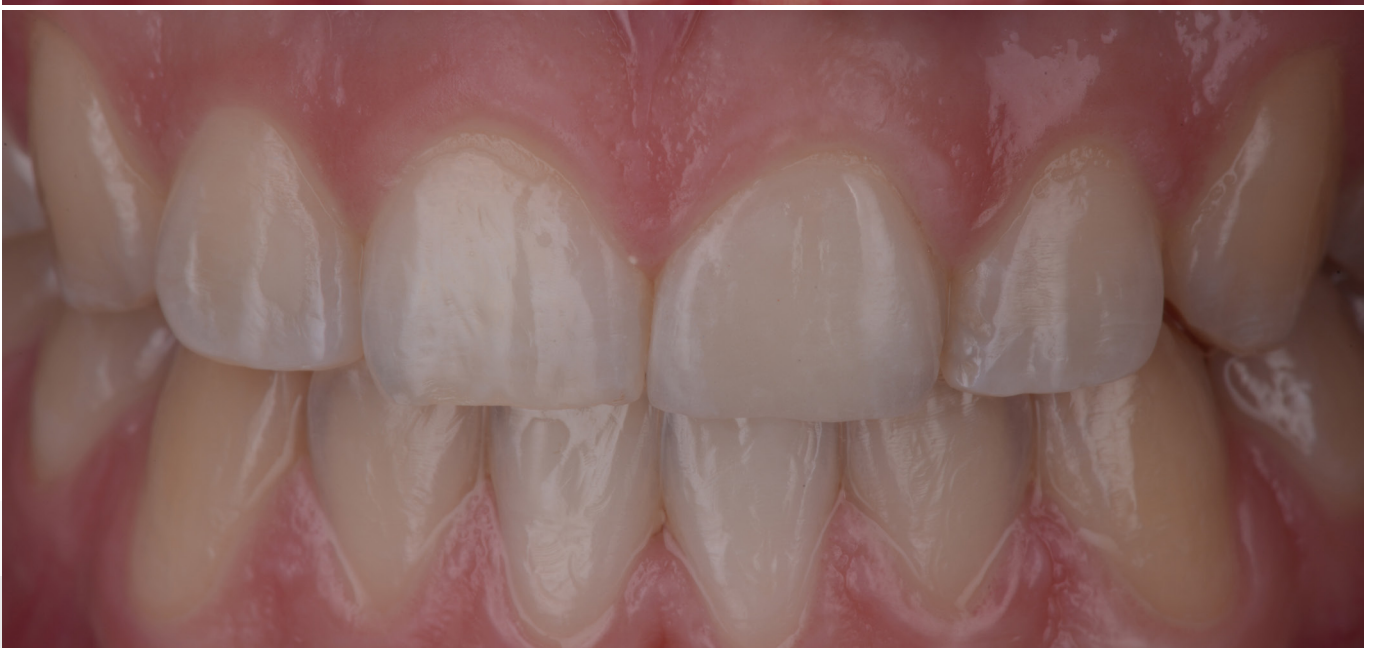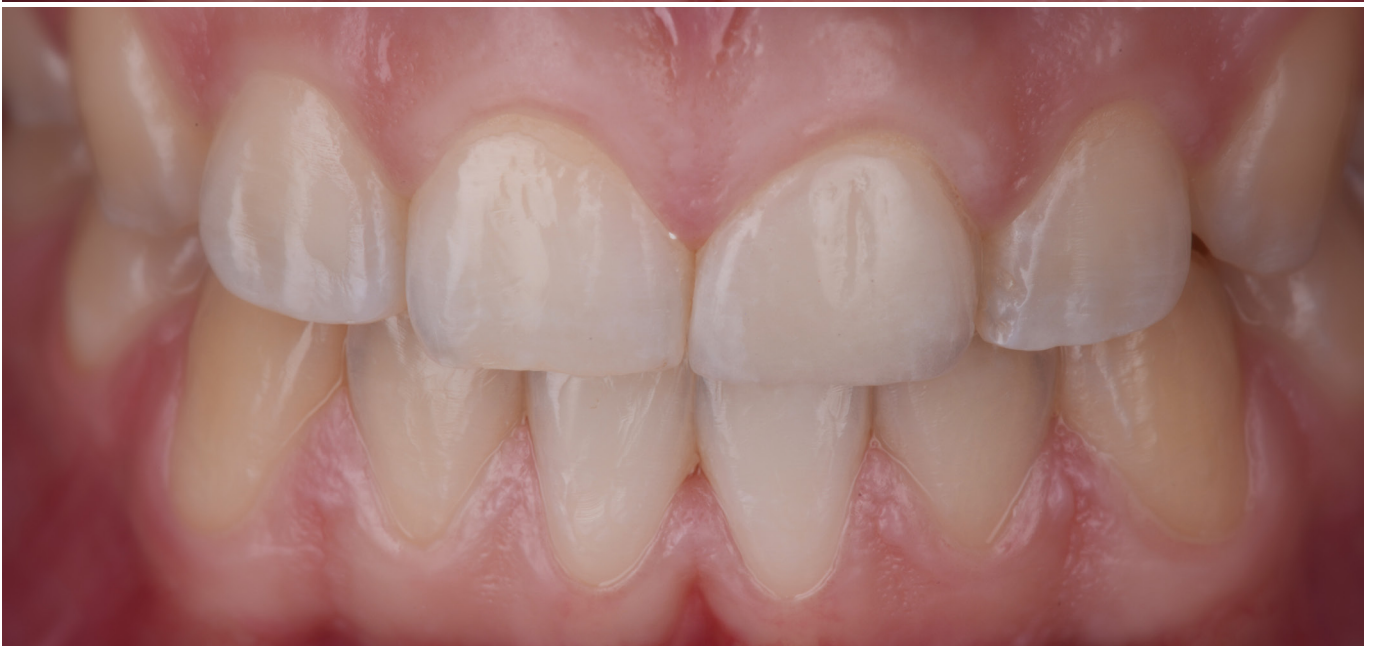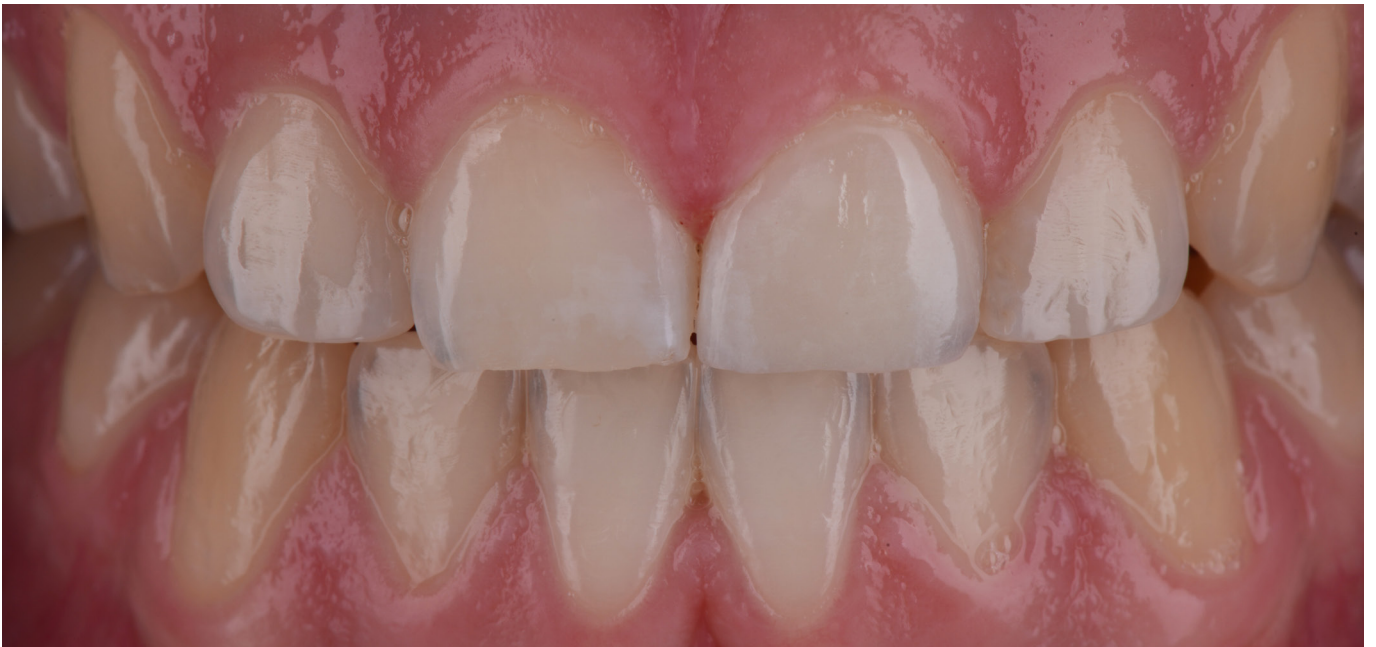Post operative images are critical, not only to see the outcome of the case, but to also check for any clinical errors. In this case, after the veneer was fixed an after image showed that some extra cement was still visible at the margin area, as well as another surprise in the patient's mouth.



**18.**

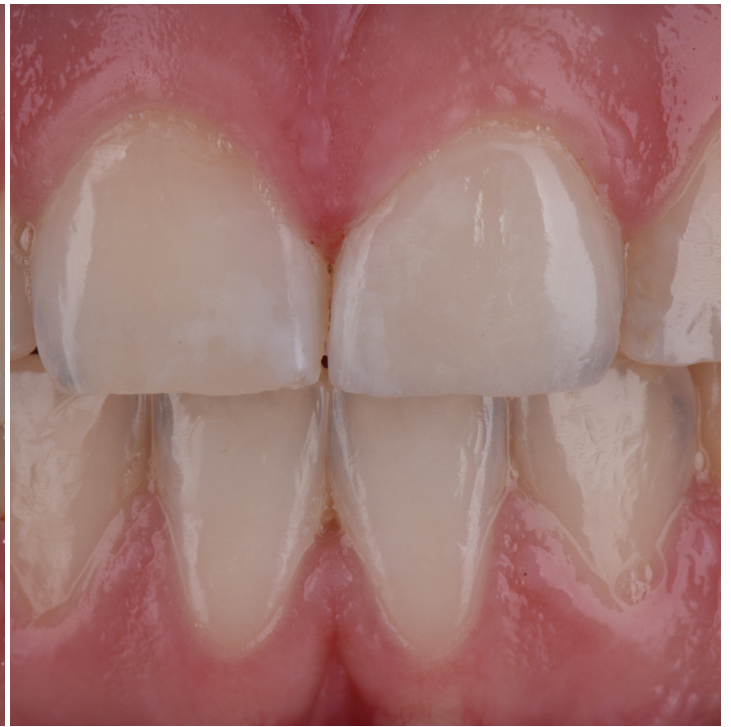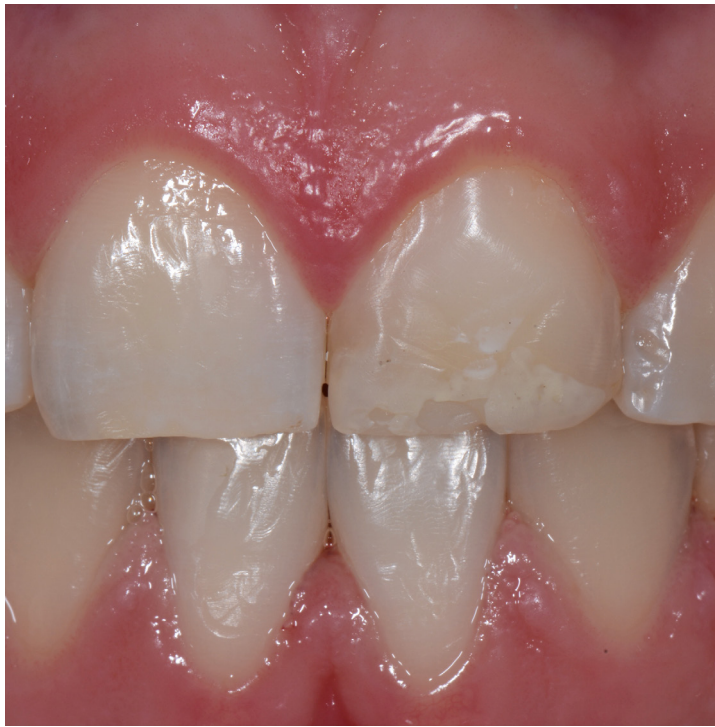Once the case is finished, photography helps observe the final outcome. Utilising different styles of photographic imaging, it can be clearly seen if the restoration has been a success or a failure. To check the work a standard dual point flash image is usually taken, as well as a diffused dual point flash image and a polarised image.






**19-21.**

The restoration should also look harmonious when observing it from all angles.




**22.**  
Although many steps and much care were taken for just one tooth, in order for a good “after” the “before” must also be understood.



#### In the end...

The patient is aware of your efforts and in turn becomes emotionally attached to your restoration.

The Patient then becomes a walking advertisement for your skills and will always represent where the treatment came from.



**JOSHUA POLANSKY**  
Dental Technician  
Photographer

Joshua Polansky earned his Bachelor of Arts degree, Summa Cum Laude, from Rutgers University in 2004. While working part-time at a dental laboratory, he took advantage of an opportunity to apprentice with distinguished master technician, Olivier Tric of Oral Design Chicago. Mr. Tric opened Joshua's eyes to a whole new world of possibilities. He made the decision to become a master dental technician following the path that Tric had forged. He continued to acquire technical skills by studying in Europe with other mentors and experts in the field such as Klaus Muttertheis. Joshua earned his Masters degree in dental ceramics at the UCLA Center for Esthetic Dentistry under Dr. Edward McLaren. Joshua Continued his training under Jungo Endo and Hiroaki Okabe at UCLA's advanced prosthodontics and maxillofacial program working on faculty and residents cases. Joshua currently resides in Cherry Hill, NJ where he is the owner and operator of Niche Dental Studio

Joshua is a key opinion leader for major dental manufacturers such as GC America. Joshua sits on the advisory/editorial board for Inside Dental Technology (IDT), and Inside Dentistry. Joshua has been published throughout the years in many publications such as the American Academy of Cosmetic Dentistry's JCD, Quintessence's QDT, and The Journal Of Prosthetic Dentistry (JPD). Joshua holds a steady lecture schedule throughout the United States and abroad teaching others the skills he has acquired from the mentors he has been so fortunate to have had.





**labline**

[www.lablinemagazine.com](http://www.lablinemagazine.com)



**facebook**

[www.facebook.com/  
lablinemagazine](https://www.facebook.com/lablinemagazine)



**DentAvantgArt**

9400 Sopron, Virág völgyi u. 59.  
[www.dentavantgart.hu](http://www.dentavantgart.hu)  
[info@dentavantgart.hu](mailto:info@dentavantgart.hu)